

Case Report

Fatal cryptococcosis presenting as hepatobiliary dysfunction in an ALL patient

Brandon R. McNew^{a,*}, Ayman El-Sheikh^a, Patricia A. Kirby^b, Warren P. Bishop^c and Ghada A. Abusin^a

^aDepartment of Pediatrics, Division of Pediatric Hematology-Oncology and Bone Marrow Transplantation, Carver College of Medicine, University of Iowa Hospitals and Clinics, Iowa City, IA, USA

^bDepartment of Pathology, Carver College of Medicine, University of Iowa Hospitals and Clinics, Iowa City, IA, USA

^cDepartment of Pediatrics, Division of Pediatric Gastroenterology, Carver College of Medicine, University of Iowa Hospitals and Clinics, Iowa City, IA, USA

Received 11 February 2014

Revised 11 April 2014

Accepted 11 April 2014

Abstract. Although current therapies for acute lymphoblastic leukemia (ALL) in children provide high cure rates, invasive fungal infections remain a significant source of mortality. We report a fatal case of cryptococcosis presenting as hepatic dysfunction in a patient with ALL and Down syndrome. Autopsy results confirmed *Cryptococcus* septicemia with involvement of lungs, liver, and lymph nodes. The severity of the fungal sepsis and underlying immunosuppression probably contributed to the unusual presentation and fatal outcome. This report highlights the need to consider cryptococcal infection as a cause of sepsis syndrome in immunocompromised patients when bacterial cultures are negative.

Keywords: *Cryptococcus neoformans*, pediatric, acute lymphoblastic leukemia, hepatobiliary dysfunction, Down syndrome

1. Introduction

While current advances in pediatric acute lymphoblastic leukemia (ALL) therapies have enhanced the cure rate, significant morbidity and mortality still result from systemic infections. [1]. Chemotherapies that suppress T-cell immunity (e.g., intensive glucocorticoid therapy), periods of prolonged neutropenia, severe oral and/or gastrointestinal mucosal injury, and the presence of central venous catheters are all risk factors for such infections. Early identification of invasive fungal infection (IFI) continues to be a major

problem. The clinical presentation is often subtle, non-specific, and in the context of multiple complex confounding variables [2]. Confirmation of IFI is often a difficult task as histologic diagnosis typically requires invasive procedures, fungal cultures have low sensitivity, imaging studies are non-specific, and serum marker results (e.g., galactomannan and β -D-glucan) are difficult to interpret in a patient with a complex presentation [3]. Delay in treatment can be costly for the patient, as IFI may progress slowly or quite rapidly to dissemination and even death.

We describe a challenging case of a pediatric patient with Down syndrome and ALL in remission who presented septic with hepatobiliary dysfunction of unclear etiology, found to have disseminated *Cryptococcus neoformans* infection at autopsy.

*Correspondence: Brandon McNew, MD, 200 Hawkins Drive-2518 JCP, University of Iowa Hospitals and Clinics, Iowa City, IA 52242, USA. Tel.: +1 319 353 7110; Fax: +1 319 356 7659; E-mail: brandon-mcnew@uiowa.edu.

2. Case report

A five year-old Caucasian male with Down syndrome was diagnosed at 3 years of age with pre-B cell ALL. He initially presented with irritability and limping for 2 months. A complete blood count showed White Blood Count (WBC) 8,400/mm³ with circulating blasts (1,360/mm³), and a bone marrow biopsy revealed hypercellular bone marrow with 80% lymphoid blasts. Cytogenetic chromosomal analysis revealed only constitutional extra copies of chromosome 21 and cytogenetic Fluorescent In situ hybridisation analysis was negative for ABL/BCR, TEL/AML1, or MLL rearrangements. Cerebrospinal fluid cytopsin was negative for blasts. He was enrolled in Children's Oncology Group study AALL0331 and received 4 weeks of 3-drug standard induction chemotherapy including daily oral dexamethasone. He achieved complete remission with negative minimal residual disease by day-29. He was then treated according to the standard risk arm of the protocol (Regimen SS-IV) [4]. Induction, Consolidation, Interim Maintenance, and Delayed Intensification courses of therapy were uneventful. His chemotherapy was not interrupted and he continued on *pneumocystis jiroveci* pneumonia prophylaxis and nystatin as antifungal prophylaxis throughout. After this intensive chemotherapy, he started maintenance phase of ALL therapy. Each cycle of maintenance therapy included oral dexamethasone for 5 days every 4 weeks, oral methotrexate weekly and oral mercaptopurine daily.

During maintenance cycle-3 (approximately one year into therapy), our patient developed perioral dermatitis and concurrent elevations in hepatic alanine transaminase (ALT). The dermatitis was mild, waxing and waning over time, with complete resolution thought to be prevented by a perpetual lip licking habit. The ALT initially was 2–4 times the upper limit of normal but increased gradually to a peak level of 25 times the upper limit of normal during cycle-4, maintaining levels of approximately 10–20 times the upper limit of normal throughout both cycle-4 and 5 of therapy. His perioral dermatitis and ALT elevation showed improvement during cycles-6 and 7 of maintenance therapy without a reduction in medication dosages. However, his perioral dermatitis showed progressive worsening during cycle-8 after cutting his bottom lip as a result of a fall while running. ALT levels coincidentally rose to almost 10 times the upper

limit of normal during the same time period. Of note, corresponding AST levels never rose > 180 U/L (upper limit of normal 45 U/L), and highest bilirubin recorded over the same time period was 1.4 mg/dL (upper limit of normal 1.0 mg/dL).

By cycle-9 of maintenance chemotherapy (approximately 2.5 years into therapy), his perioral dermatitis became persistent and refractory to topical antibiotics, and he developed concurrent perianal dermatitis. Oral Herpes simplex virus (HSV) culture and direct fluorescent antibody (DFA), evaluated at multiple points over the previous 6 months, continued to be negative, and perianal lesion cultures showed non-specific mixed intestinal bacteria flora species. Dental exam revealed poor oral hygiene with seven dental caries, generalized moderate plaque, inflamed gingival tissues, attrition, and hypodontia secondary to fusion which was consistent with bruxism. The delay in healing of his lip laceration was attributed to his lip licking habit, compromised by his immune status and monthly systemic steroid therapies. Complete dental corrections were planned for after completion of chemotherapy and removal of the central venous catheter. Dermatology was regularly involved. Multiple trials in topical care evaluating the effectiveness of A+D ointment, Vaseline, lip balm, mupirocin, triple antibiotic ointment, magnesium oxide, zinc oxide, nystatin, clotrimazole, miconazole, and hydrocortisone 1% ointment provided no sustained improvement of his oral and perianal dermatitis.

On day-17 of cycle-10 (approximately 2.7 years into therapy), patient was admitted for an acute onset of severe yet painless mucosal blisters and white plaque ulcerations involving his tongue and inner lip, concurrent worsening of perianal lesions. Parents reported mild fatigue and irritability, a history of alternating diarrhea and constipation. They denied any issues with eating or drinking, fevers or chills, other lesions or concurrent rashes. Initial laboratory testing revealed mild leucopenia (WBC 2500/mm³) without neutropenia (absolute neutrophil count ANC 1620/mm³), anemia (hemoglobin 9.7 g/dL), and thrombocytopenia (platelet count 148,000/mm³). He had no fever. Aerobic oral bacterial culture, HSV oral culture, and HSV-DFA were obtained. Empiric therapies of acyclovir and cephalexin were started. Oral bacterial culture was determined to be negative at 48 h without culture growth, whereas perianal culture revealed few mixed intestinal flora including two species of the *Klebsiella*/Enterobacter group, *Pseudomonas aeru-*

ginosa, and *Enterococcus* species. HSV-DFA was negative and acyclovir was discontinued. Following a mild improvement on oral antibiotics and no obvious discomfort, he was discharged home on day-4 of hospital admission on oral cephalexin. Liver function was not assessed during this admission because no apparent hepatobiliary symptomatology including jaundice was noted during his stay. Liver function testing (bilirubin and ALT), recommended every 12 weeks while in maintenance per COG AALL0434 protocol, was being monitored monthly because of his significant history of previous elevations. Testing performed 3 weeks prior had revealed a total bilirubin level of 1.2 mg/dL, stable from an elevation of 1.1 mg/dL noted 3 months prior, ALT elevated at 92 U/L, improved from 197 U/L noted 3 months prior.

On patient's 3rd day at home following discharge, his parents reported changes in his behavior including increased irritability, sleepiness, decreased appetite, increased thirst, and abdominal bloating (perceived as excess gas). On his 4th day home, parents noted that his skin and eyes looked yellowed. With known history of having mild bilirubin elevation in the past, recent antibiotic history to potentially explain his abdominal bloating, and next scheduled appointment 3 days away, parents were offered reassurance but encouraged to seek immediate medical evaluation for symptomatic progression.

Six days following his previous hospital discharge and one day before his next scheduled clinic visit for chemotherapy, patient was re-admitted to the hospital, febrile with temperature 38.3°C, tachycardic with heart rate 140 beats per minute, tachypneic with respiratory rate 28 breaths per minute, hypertensive with blood pressure 127/76 mmHg, somnolent and severely jaundiced with marked abdominal distension. Laboratory blood testing revealed hepatobiliary dysfunction of unclear etiology with total bilirubin 27.5 mg/dL, direct bilirubin 21.9 mg/dL, prothrombin time (PT) 29 sec, INR 3.1, partial thromboplastin time (PTT) 150 sec, AST 82 U/L, ALT 72U/L, alkaline phosphatase 104 U/L, ammonia 52 µmol/L, albumin 2.3 g/dL, WBC 1,100/mm³, ANC 780/mm³, hemoglobin 7.5 g/dL and platelets 186,000/mm³. Blood cultures were obtained, and he was empirically started on broad-spectrum antibiotics (cefepime and vancomycin) for suspected bacterial peritonitis. Abdominal ultrasound showed moderate ascites, a distended gallbladder containing sludge but no calculi, a non-dilated common bile duct, no evidence of dilatation of

intra or extra-hepatic biliary radicals, normal liver and spleen, and an unremarkable pancreas. Doppler studies confirmed patency of all major vessels. Paracentesis was performed yielding clear yellow non-pyogenic fluid (albumin < 1.0 g/dL, serum ascites-albumin gradient < 2.4, < 4000 RBCs, only 50 nucleated cells identified; 40 monocytes, 7 neutrophils, 2 lymphocytes, 1 eosinophil) without evidence of organisms. Aerobic and anaerobic cultures were obtained. Fungal cultures were not obtained as an invasive fungal infection was not highly suspected. Viral antibody testing for Hepatitis A, B, and C, EBV, CMV, HSV, and Adenovirus provided negative results.

Despite all supportive measures, he developed significantly worsening hyperbilirubinemia, his total bilirubin level rising to 43 mg/dL. He required increased oxygen and developed hypercapnia which was not reduced by bi-level positive airway pressure (BiPAP) respiratory support. Endotracheal intubation was performed. During intubation, patient became asystolic and chest compressions were initiated. At this time, a second paracentesis was performed, obtaining a small amount of bilious fluid. Following a successful resuscitation, blood cultures taken on admission yielded preliminary growth results of yeast. Patient was immediately started on IV fluconazole for suspected candidiasis. Amphotericin was not initiated out of fear of causing further and perhaps unnecessary harm to already failing organ systems. Within 2 hours of initiating antifungal therapy, he suffered a second and fatal cardiopulmonary arrest.

Results of previously collected admission and day-2 blood cultures (Bactec+ aerobic/f culture vial) and second paracentesis fluid culture unexpectedly identified *Cryptococcus neoformans* (serotype not identified). Histology and tissue cultures obtained at autopsy (requested by his parents) identified *Cryptococcus* septicemia. Methanamine Silver and Periodic Acid-Schiff Diastase staining assisted in the identification of encapsulated yeast. There were extensive, predominantly intravascular cryptococcal organisms in the lungs (Fig. 1.) associated with hyaline membrane formation accompanied by very few acute inflammatory cells and intraalveolar and interstitial hemorrhages. Intraalveolar macrophages were noted to be increased. There was centrilobar congestion with focal necrosis with abundant cryptococcal organism in the liver sinusoids (Figs 2 and 3). Regenerative changes were also noted, but the pathology was dominated by the extensive bland cholestasis seen

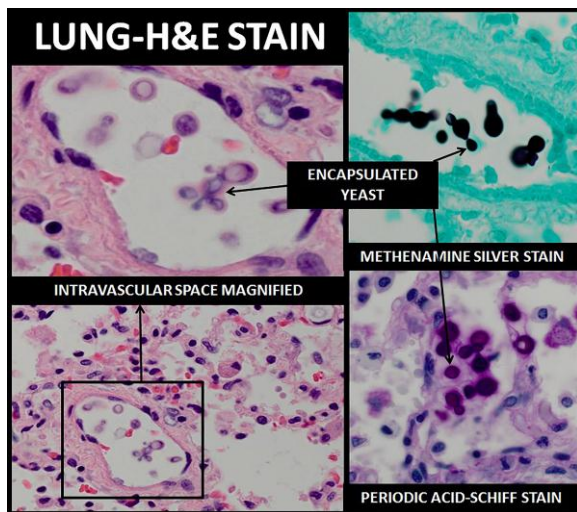


Fig. 1. Lung pathology at time of autopsy. Diffuse encapsulated yeast depicted viewed on H& E stain, highlighted by Methanamine Silver and Periodic Acid-Schiff Diastase stains. (Colours are visible in the online version of the article; <http://dx.doi.org/10.3233/JPI-140416>)

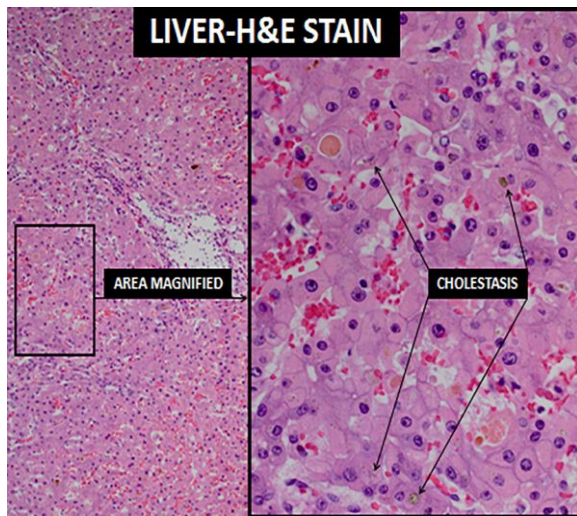


Fig. 2. Liver pathology at time of autopsy. Bland cholestasis, depicted as brown pigmentation, present in hepatocytes. No hepatocellular necrosis was identified. (Colours are visible in the online version of the article; <http://dx.doi.org/10.3233/JPI-140416>)

in the hepatocytes, canaliculi, and intralobar bile ducts. The portal triads were free of inflammation and there was no bile duct abnormality or bile stasis in the ducts. The gallbladder showed an intact mucosa without significant inflammation.

Rare intravascular cryptococcal organisms were also observed in the brain and heart, and occasional organisms were seen in the red pulp of the spleen and

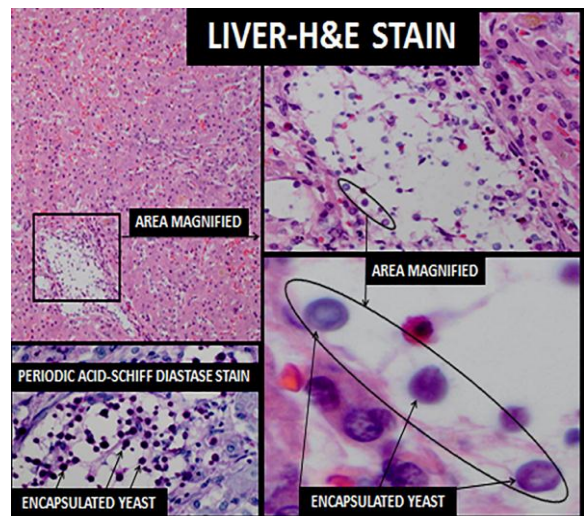


Fig. 3. Liver pathology at time of autopsy. Diffuse encapsulated yeast depicted on H&E stain, highlighted with Periodic Acid-Schiff Diastase stain. (Colours are visible in the online version of the article; <http://dx.doi.org/10.3233/JPI-140416>)

renal capillaries. Large pools of cryptococcal organisms were seen throughout the subcarinal nodes, while a few were noted in the subcapsular sinuses and amongst medullary macrophages in the perihepatic nodes. Although numerous cryptococcal organisms were seen in the paravertebral fat and soft tissues, no organisms were identified in the bone marrow. CSF analysis and culture were not performed as part of the autopsy.

3. Discussion

Cryptococcus is a ubiquitous fungal pathogen known to cause disease in immunocompromised populations, specifically in those with HIV or who are solid organ transplant recipients [4]. Initial cryptococcal infections are generally acquired by inhalation of the yeast into the lungs from contaminated soil or avian nests [5,6]. Reports of invasive cryptococcal infections are rare in adult populations, even more so in pediatric patients, and are least common in pediatric ALL patients in spite of their immunocompromised status [6–11]. A retrospective review of the Pediatric Health Information System database performed by Joshi et al from 2003–2008, evaluated the medical records of patients less than 19 years of age admitted to 42 contributing free-standing children's hospitals with the ICD-9 diagnosis codes for cryptococcosis or

cryptococcal meningitis. This extensive multi-institutional review yielded only 65 reports of cryptococcal infection, an infection admission rate of 6.2 per million hospitalizations, with only 9 (13.8%) of the 65 patients suffering from ALL [12]. *Cryptococcus* in pediatric case reports outside this study typically presents as pulmonary or central nervous system involvement, persistent fevers at time of diagnosis an often associated finding that prompts the initial investigative workup [7,8,10–12]. Although a much less common presentation, cutaneous lesions have been described as the predominant feature of disseminated cryptococcosis in the pediatric literature [13]. In the adult literature, cutaneous lesions are estimated to be present in as many as 5–10% of patients who have disseminated cryptococcosis, patients usually asymptomatic with painless lesions on the head and neck, and less often, on the limbs and the trunk [14]. Hepatobiliary dysfunction, a rare predominant feature of disseminated *Cryptococcus* in pediatric patients, has only been described seven times in the English literature [5]. While disseminated candidiasis presenting as hepatobiliary dysfunction in pediatric ALL patients has been described, no cases of disseminated cryptococcosis presenting as hepatobiliary dysfunction in pediatric ALL patients have been described [1, 15,16]. Disseminated disease and sudden death of a pediatric ALL patient secondary to *Cryptococcus neoformans* while in remission without liver involvement has been described once [10].

Common presenting symptoms of pediatric patients found to have hepatosplenic fungal infections include fever, nausea and/or vomiting, hepatosplenomegaly, and jaundice. A retrospective 10-year review performed in a tertiary medical center in Taiwan from 1999–2009 investigated the clinical characteristics of 15 pediatric patients identified to have hepatosplenic fungal infections [15]. Ten patients had the diagnosis of acute leukemia (5 with acute myeloid leukemia, 5 with ALL). All 15 patients presented with fever (> 38.0°C), and most had abdominal pain (80%), nausea and/or vomiting or hepatosplenomegaly (80%), and jaundice (73%). Less prevalent but still important findings included cutaneous lesions (47%) and respiratory symptoms (53%). The detection rate of computed tomography (15/15, 100%) was found superior to abdominal sonography (10/15, 67%, $p = 0.01$). Ten (91%) of the 11 patients with microbiologic evidence were infected by *Candida* species, the other organism identified was *Aspergillus* [15].

Commonly associated risk factors for invasive fungal infections typically include prolonged neutropenia, presence of intravascular catheters, disruption of mucosal barriers, and the administration of broad-spectrum antibiotics. ALL therapy includes corticosteroids which impair CD4 T-cell function, increasing the susceptibility of ALL patients to invasive fungal infections [8]. Patients with Down syndrome and ALL have been found to be significantly more likely to experience mucositis, microbiologically documented infections, and cellulitis in comparison to non-Down Syndrome counterparts [17]. Furthermore, Down syndrome patients are at increased risk for treatment-related death, infection occurring in as many as 72% of cases [1].

Retrospectively, it is conceivable that the acute onset of painless mucosal blisters/ulcerations and concurrent worsening of perianal lesions 10 days prior to our patient's death were stigmata of disseminated *Cryptococcus*. We believe the interpretation of the lesions was particularly confusing because of their apparent painless nature. Despite multiple examiners of the lesions during his previous admission, bacterial and viral cultures being performed, specific fungal cultures or fungal antigen testing of the lesions were never done. The only aerobic bacterial culture taken from the perioral dermatitis was performed 10 days prior to his death. Although the results did not grow any *Cryptococcus*, which may have been possible on routine bacteriological media, the culture was declared negative after 48 h and not observed longer. Unfortunately, no biopsies were taken from the lesions at time of autopsy to confirm the suspicion of them being a result of *Cryptococcus*.

In retrospect, had our patient's developing jaundice been evaluated sooner and invasive fungal infection, specifically *Cryptococcus*, been suspected as a potential underlying cause to his presentation, his death may have been avoidable. However, for a multitude of reasons, recognizing the retrospective obvious was quite difficult. For starters, recognizing the significance of his jaundice several days prior to his death was definitely clouded by his history of having transient elevations in transaminases and bilirubin while receiving chemotherapy. Secondly, other than his well-known issues of chronic perioral and perianal dermatitis, our patient had an otherwise well clinical appearance leading up to his final days. Although his appearance may have been perhaps confounded by his naturally happy demeanor with tolerance for dis-

comfort, he was also seldom ill throughout his therapy and there was little extraordinary history strongly suggestive of an invasive fungal infection. He was admitted only twice during Maintenance therapy for fever, both events occurring between 7 and 8 mo prior to his death, presenting both times with upper respiratory tract infection symptomatology and without neutropenia. He was discharged after 72 h of empiric antibiotics, with at least 24 h of no fever and blood cultures revealing no growth. He was only neutropenic ($ANC < 500/mm^3$) twice during therapy, once during delayed intensification with no identified cause, and once again at time of death. He had no significant travel history outside the state or country, did not live on a farm, and had no notable exposure to contaminated soil or avian nests.

While invasive fungal infections have been linked to patients with liver dysfunction, particularly patients with acute on chronic liver failure [18,19], it is difficult to interpret what role our patient's chronically elevated transaminases played in the development of his disseminated cryptococcosis. Our patient's AST and ALT levels were only mildly elevated on admission several days prior to his death, relatively unchanged from levels obtained one month prior. This argues against him having acute liver failure. His chronically elevated transaminases, particularly his ALT, which was most significantly elevated 16 mo before his death, were attributable to his medications methotrexate and mercaptopurine. Both doses were escalated because of medication tolerance as defined by chemotherapy protocol and both escalated 25% in dose over 3 mo leading up to this event. Both medication doses were never reduced during maintenance, as significant elevations were only transient. His mercaptopurine dose was actually escalated once more during the remainder of this therapy as a result of medication tolerance as defined by chemotherapy protocol. Chronically elevated transaminases secondary to medications does not equate to chronic liver disease. Retrospectively, based on autopsy findings showing a liver devoid of evidence suggesting chronic inflammation, it is most likely that our patient's hepatobiliary dysfunction at his last admission was a manifestation of disseminated *Cryptococcus*, and his disseminated *Cryptococcus* was not a consequence of his past history of chronically elevated AST and ALT levels.

Although continued research supports the use of antifungal prophylaxis in pediatric oncology patients,

these data are derived primarily from adult patients and thus the optimal agent to utilize is unclear in children [20]. Our patient was prophylactically on daily nystatin. Fluconazole, started only hours before his death, was chosen to cover the much more likely diagnosis of candidiasis. Current literature supports the use of IV amphotericin B deoxycholate (1 mg/kg per day) or IV liposomal amphotericin (4 to 6 mg/kg day) plus oral flucytosine (100 mg/kg per day 4 divided doses) for at least 4 weeks as induction therapy for cryptococcal disease in non-HIV-infected, non-transplant hosts [8].

Cryptococcosis should be considered in immunocompromised children presenting with presumed sepsis and/or hepatobiliary dysfunction, particularly those with negative bacterial cultures. Prompt identification and initiation of appropriate therapy is critical in preventing mortality. Examination of persistent and particularly painless skin lesions for fungal infections including *Cryptococcus* should be considered.

Acknowledgements

We would like to acknowledge Dr. Charles Grose and Dr. Sue O'Dorisio for their editorial contributions, Dr. Grose particularly for his professional insight into this difficult infectious disease case. We would also like to acknowledge NIH T32 grant support to Brandon Robert McNew, Grant #T32 HL080070.

References

- [1] Lund B, Åsberg A, Heyman M, Kanerva J, Harila-Saari A, Hasle H et al. Nordic Society of Paediatric Haematology and Oncology. Risk factors for treatment related mortality in childhood acute lymphoblastic leukaemia. *Pediatr Blood Cancer* 2011; 56(4): 551-9.
- [2] Villarreal M, Avilés CL, Silva P, Guzmán AM, Poggi H, Alvarez AM et al. Risk factors associated with invasive fungal disease in children with cancer and febrile neutropenia: a prospective multicenter evaluation. *Pediatr Infect Dis J* 2010; 29(9): 816-21.
- [3] Leventakos K, Lewis RE, Kontoyiannis DP. Fungal infections in leukemia patients: how do we prevent and treat them? *Clin Infect Dis* 2010; 50(3): 405-15.
- [4] Maloney K. Children's oncology group [homepage on the Internet]. 2013 [cited 2014 Mar 11]. Available from: <https://members.childrensoncologygroup.org/Prot/AALL0331/AALL0331DOC.pdf>
- [5] Pappas PG. Cryptococcal infections in non-HIV-infected patients. *Trans Am Clin Climatol Assoc* 2013; 124: 61-79.
- [6] Zhang C, Du L, Cai W, Wu Y, Lv F. Isolated hepatobiliary cryptococcosis manifesting as obstructive jaundice in an

- immunocompetent child: case report and review of the literature. *Eur J Pediatr* 2013; DOI 10.1007/s00431-013-2132-2.
- [7] Hammond SP, Marty FM, Bryar JM, DeAngelo DJ, Baden LR. Invasive fungal disease in patients treated for newly diagnosed acute leukemia. *Am J Hematol* 2010; 85(9): 695-9.
- [8] Heath JL, Yin DE, Wechsler DS, Turner DA. Successful treatment of disseminated cryptococcal infection in a pediatric acute lymphoblastic leukemia patient during induction. *J Pediatr Hematol Oncol* 2012; 34(4): e161-3.
- [9] Huang KY, Huang YC, Hung IJ, Lin TY. Cryptococcosis in nonhuman immunodeficiency virus-infected children. *Pediatr Neurol* 2010; 42(4): 267-70.
- [10] Lascari AD, Pearce JM, Swanson H. Sudden death due to disseminated cryptococcosis in a child with leukemia in remission. *South Med J* 1997; 90(12): 1253-4.
- [11] Mavinkurve-Groothuis AM, Bokkerink JP, Verweij PE, Veerman AJ, Hoogerbrugge PM. Cryptococcal meningitis in a child with acute lymphoblastic leukemia. *Pediatr Infect Dis J* 2003; 22(6): 576.
- [12] Joshi NS, Fisher BT, Prasad PA, Zaoutis TE. Epidemiology of cryptococcal infection in hospitalized children. *Pediatr Infect Dis J* 2010; 29(12): e91-5.
- [13] Tuerlinckx D, Bodart E, Garrino MG, Weemaes G, de Bilderling G. Cutaneous lesions of disseminated cryptococcosis as the presenting manifestation of human immunodeficiency virus infection in a twenty-two-month-old child. *Pediatr Infect Dis J* 2001; 20(4): 463-4.
- [14] Müller CS, Schmaltz R, Vogt T. Secondary cutaneous cryptococcosis mimicking a malignant ulcerated tumor of the facial skin in an immunosuppressed patient. *Eur J Dermatol* 2010; 20(5): 657-8.
- [15] Yen TY, Huang LM, Lee PI, Lu CY, Shao PL, Chang LY. Clinical characteristics of hepatosplenic fungal infection in pediatric patients. *J Microbiol Immunol Infect* 2011; 44(4): 296-302.
- [16] Hernández Marqués C, Lassaletta-Atienza A, González-Vicent M, Sevilla J, Molina B, Andión M et al. [Hepatosplenic candidiasis in paediatric haematology-oncology patients]. *An Pediatr (Barc)* 2011; 75(1): 26-32 (in Spanish).
- [17] Rabin KR, Smith J, Kozinetz CA. Myelosuppression and infectious complications in children with Down syndrome and acute lymphoblastic leukemia. *Pediatr Blood Cancer* 2012; 58(4): 633-5.
- [18] Lin LN, Zhu Y, Che FB, Gu JL, Chen JH. Invasive fungal infections secondary to acute-on-chronic liver failure: a retrospective study. *Mycoses* 2013; 56(4): 429-33.
- [19] Godbole G, Shanmugam N, Dhawan A, Verma A. Infectious complications in pediatric acute liver failure. *J Pediatr Gastroenterol Nutr* 2011; 53(3): 320-5.
- [20] Dvorak CC, Fisher BT, Sung L, Steinbach WJ, Nieder M, Alexander S et al. Antifungal prophylaxis in pediatric hematology/oncology: new choices & new data. *Pediatr Blood Cancer* 2012; 59(1): 21-6.